

Managing Your Patients' Immune-Related Adverse Events (irAEs)

Brianna Hoffner, MSN, ANP-BC, AOCNP

Assistant Professor, University of Colorado School of Medicine

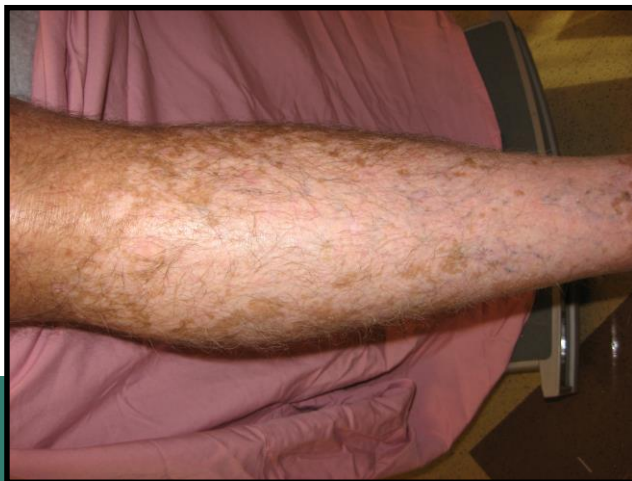Nurse Practitioner, University of Colorado Cancer Center

Overview

- Overview of immune-related adverse events
 - Skin
 - Dermatitis
 - Oral Mucosa
 - Diarrhea/Colitis
 - Endocrinopathies
 - Thyroid disorders
 - Hypophysitis
 - Diabetes mellitus
 - Adrenalitis
 - Pneumonitis
 - Hepatitis
 - Nephritis
 - Other
- Relationship between irAE and treatment response
- Case studies

Skin

- Skin events most frequent irAE for both anti-CTLA-4 and anti-PD-1 blockade in melanoma patients
 - Anti-PD-1: Approx 40% in melanoma versus 17% in NSCLC¹
- More common in anti-CTLA4 (50%) and combo (60%)²
 - Grade 3/4 rash in less than 10%²
- Includes vitiligo, rash, erythema
 - Rarely Stevens-Johnson or Toxic epidermal necrosis



1. Eigentler et al, Cancer Treatment Reviews, 2016;
2. Friedman et al, JAMA Oncology, 2016

Dermatitis

- Symptoms

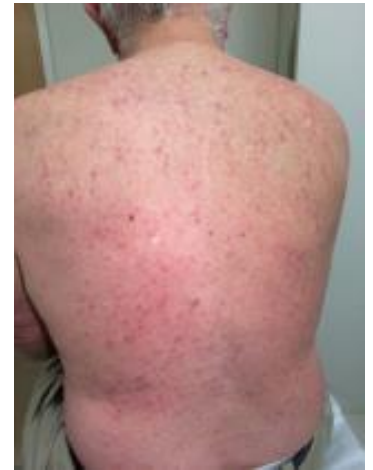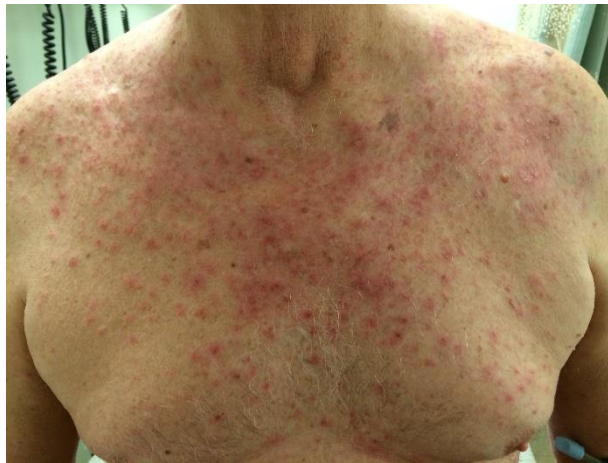- Rash
- Itching
- Fevers
- Skin desquamation and sloughing of oral mucosa in severe cases (Stevens-Johnson Syndrome, Toxic Epidermal Necrolysis)

- Work Up

- Generally diagnosed based on appearance
- Severe or treatment refractory cases may require biopsy

- Management

- Grade 1-2 managed with topical corticosteroids and oral antipruritic
 - Eval for skin infections before applying topical steroid
- Grade 3-4 systemic steroid course
 - Consider skin biopsy for histological classification



Oral Mucosa

- May include mucositis, gingivitis, and sicca (Sjogren) syndrome
- Approximately 5% of patients on checkpoint inhibitors have symptoms of dry mouth¹
 - More common in anti-PD1 agents²
- Work-up:
 - Anti-nuclear antibodies (ANA)
 - Sjogren's syndrome A & Sjogren's syndrome B (SSA/SSB) screen
- Management:
 - Oral corticosteroid rinses
 - Pilocarpine chlorhydrate
 - Viscous lidocaine
 - Good oral hygiene

Diarrhea and/or Colitis

- Diarrhea and/or colitis is the most common and potentially most serious complication of anti-CTLA-4 therapy.
 - Some trials report up to 31% of patients experiencing some grade of diarrhea, with 6% experiencing severe colitis (Hodi, 2010).
 - Bowel perforation, sepsis, and death have been reported.
- Grade 3/4 colitis more common in CTLA-4 (7%) than PD-1 (1.8%)¹
 - Approximately 8% Grade 3/4 in combination therapy²
- Median time to onset 6-8 weeks in CTLA-4 or CTLA-4/PD-1, longer in PD-1¹

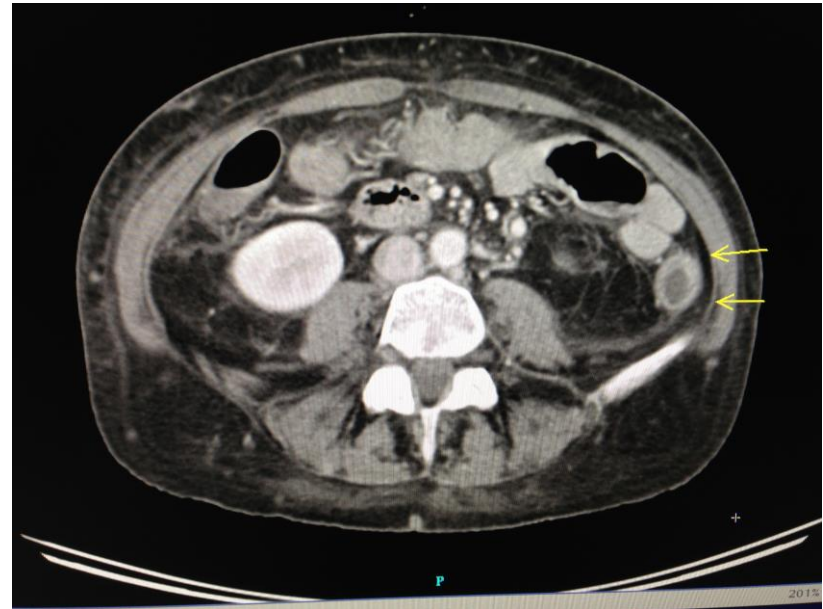
Diarrhea/Colitis

- Symptoms

- Abdominal cramping, pain
- Anorexia, dyspepsia
- Diarrhea
- Blood or mucous in stool
- Leukocytosis
- Serum electrolyte abnormalities
- Possible to have colitis without diarrhea

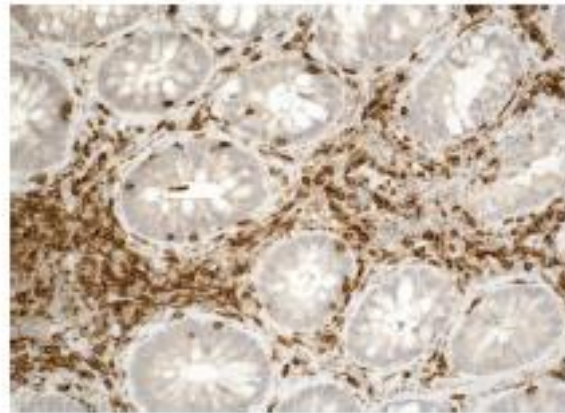
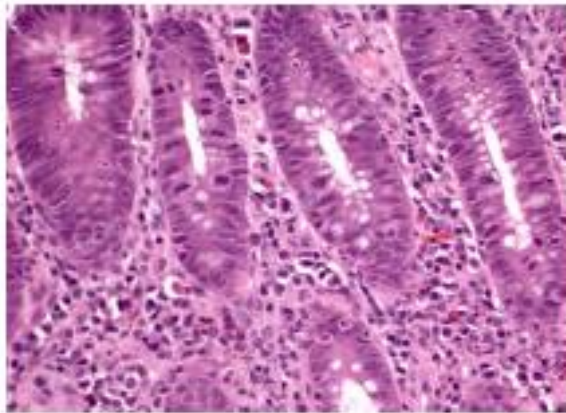
- Work Up

- Stool for c-diff, ova and parasite, blood
- CT abdomen/pelvis with IV contrast to evaluate for colonic thickening and dilatation
- Colonoscopy with biopsy

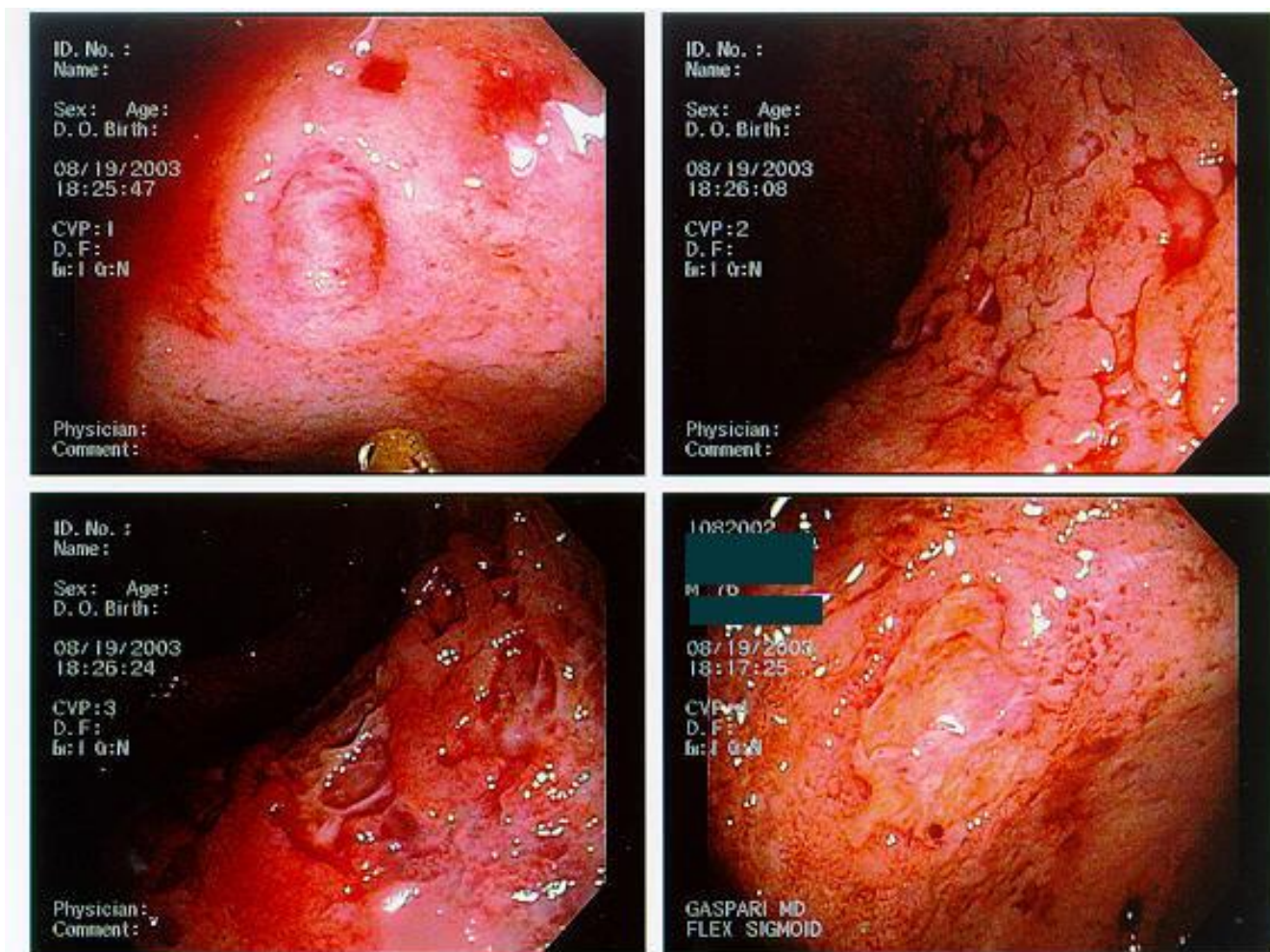


Diarrhea and/or Colitis

- Sigmoidoscopy/colonoscopy may be done if diagnosis is unclear
- Pathologic features resemble Crohn's Disease
 - Mucosal erythema and ulcerations
 - Histologic patterns include lymphocytic and neutrophil inflammation with cryptitis and, in some cases, crypt abscesses and granuloma



Diarrhea/Colitis



Diarrhea and/or Colitis

- Mild (Grade 1): <4 stools/day above baseline
 - Bland diet, proton-pump inhibitors, loperamide ± diphenoxylate/atropine
 - May delay ipilimumab until symptoms improve
- Moderate (Grade 2): ≥4 to 6 stools/day
 - Consider colonoscopy; moderate-dose steroids: 0.5 mg/kg per day of methylprednisolone; increase dose if no improvement in 24 hours
 - Hold immunotherapy
- Severe (Grade ≥3): ≥7 stools/day
 - High-dose steroids: 1 mg/kg of methylprednisolone or equivalent
 - Discontinue immunotherapy
 - If unresolved within 1 week or symptoms worsen, consider infliximab (anti-TNF alpha)
- Prevention with Budesonide (oral) –Randomized phase II trial no benefit shown¹
- Diarrhea/colitis with one checkpoint inhibitor does not prohibit use of another²

Endocrinopathies

- Approximately 5-10% of patients treated with anti-CTLA-4 and anti PD-1/PD-L1 develop endocrinopathies¹
- Many endocrine disorders do not resolve—require life-long replacement
- May include:
 - Hypothyroid/Hyperthyroid
 - Hypophysitis
 - Adrenal insufficiency
 - Diabetes

Thyroid Disorders

- Hypothyroidism most commonly seen with PD-1 (6%)¹
 - Primary hypothyroidism often preceded by transient hyperthyroidism²
 - CTLA-4 approximately 5.6% of patients
 - Many studies did not distinguish between primary thyroid dysfunction (related to thyroid gland dysfunction) and secondary thyroid dysfunction (due to hypophysitis-related pituitary dysfunction)
- Evaluation:
 - High TSH, low/normal free T4 or T3 indicate primary hypothyroidism
 - Low/normal TSH, low free T4 suggests hypothyroidism secondary to pituitary
 - TPO antibodies, thyrotropin-binding inhibitory immunoglobulins

Hypophysitis

- Inflammation of the pituitary resulting in low release of all or some of the following pituitary hormones¹:
 - Adrenocorticotrophic hormone (ACTH)
 - TSH
 - Follicle-stimulating hormone (FSH)
 - Luteinising hormone (LH)
 - Growth hormone (prolactin)
- Symptoms¹:
 - Headache
 - Fatigue
 - Muscle weakness
 - Constipation
 - Cognitive difficulties (related to thyrotropin axis)
 - Erectile dysfunction/amenorrhea (gonadotropin axis, LH/FSH)
 - Orthostatic hypotension, hypoglycemia/hyponatremia (corticotrophin deficiency, ACTH)

Hypophysitis

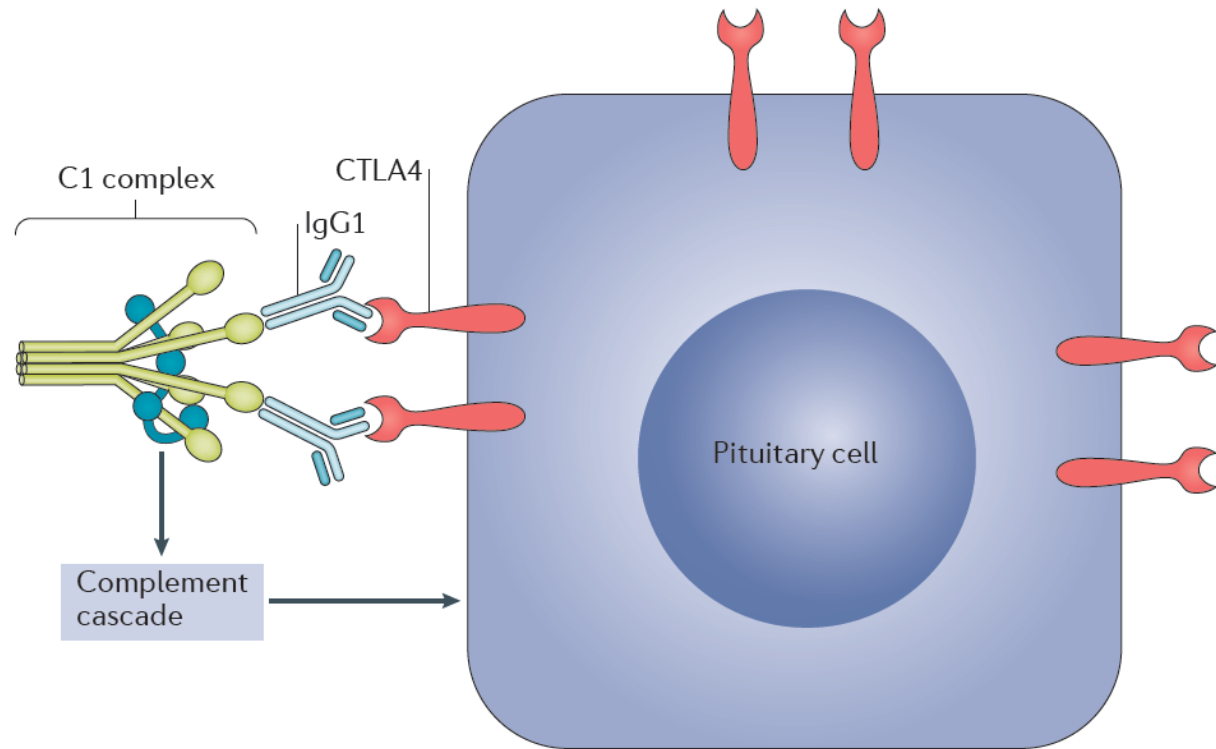
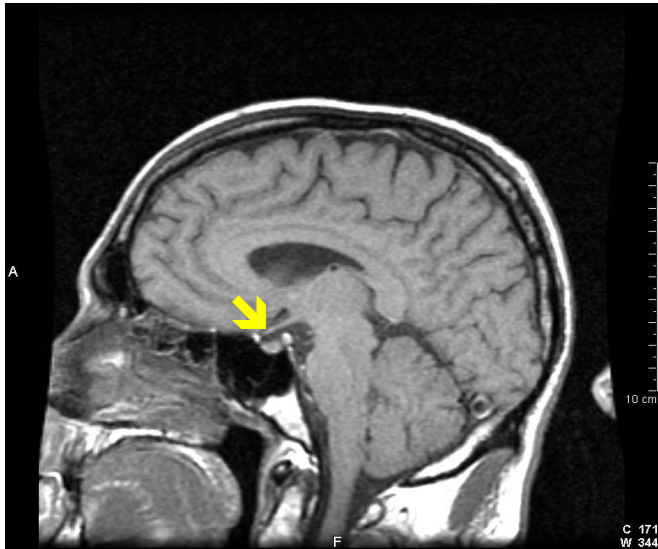


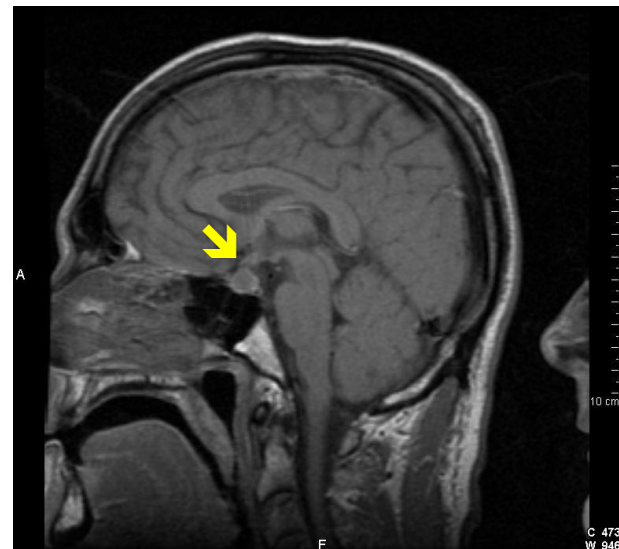Figure 2 | **Normal pituitary tissues express ectopic CTLA4 protein.** Binding to cytotoxic T-lymphocyte antigen 4 (CTLA4) autoantibodies or ipilimumab IgG1 to native CTLA4 proteins on normal pituitary tissue is thought to lead to activation of the classic complement pathway.

Hypophysitis

- Work-up
 - Evaluation of pituitary gland hormones (ACTH, TSH, FSH, LH, prolactin, cortisol)
 - MRI brain with contrast (pituitary cuts)



Pre-Yervoy



Post-Yervoy

Diabetes Mellitus

- Rare occurrence with PD-1
- Patients generally present in DKA¹
- Work up should include testing for glutamic acid decarboxylase 65 (GAD65) antibodies
- Mechanism unclear¹
 - In one study, 2 of 5 patients presented with upregulation of CD8+ T cell response to a T1DM antigen
 - 3 of 5 patients were found to have GAD65 antibodies
- Treatment with insulin therapy

Adrenalitis

- Primary adrenal insufficiency extremely rare but reported with CLTA4
- Adrenal gland enlargement can be seen on CT scans
- Work up:
 - ACTH
 - Cortisol
 - Cosyntropin stimulation test
- Management:
Replacement with oral hydrocortisone

Pneumonitis

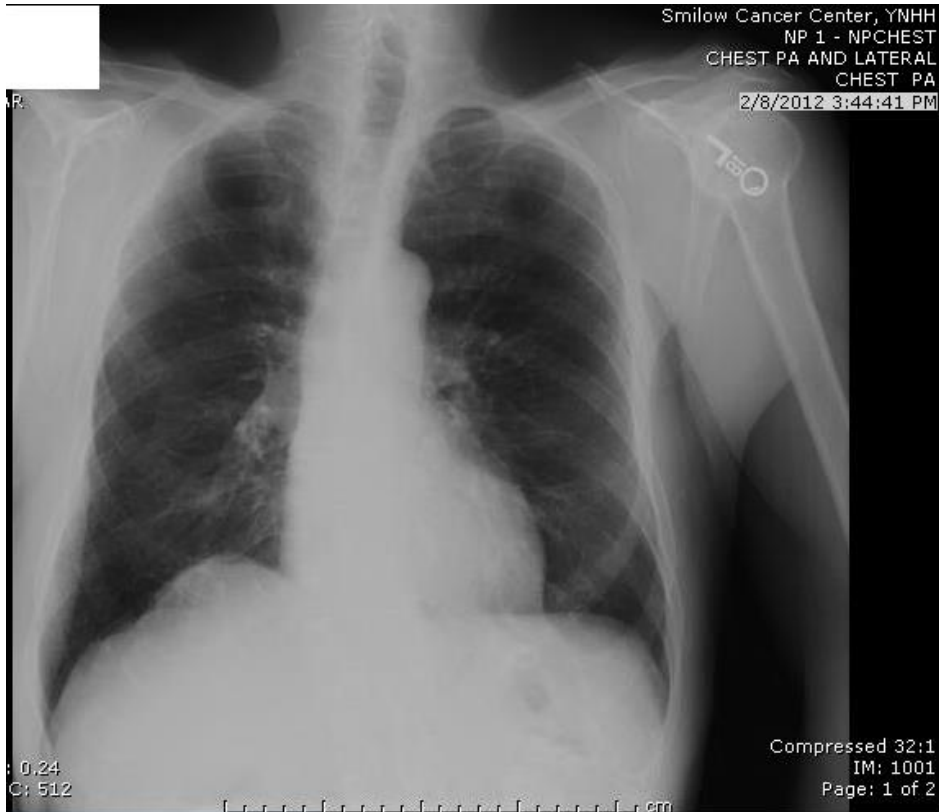
- Occurs in approximately 1-2% of patients treated with PD-1 and/or CTLA4^{1,2}
- Time to onset 9-19 weeks (earlier with Nivolumab than Pembrolizumab)²
- Symptoms:
 - Dry, unproductive cough
 - Dyspnea
 - Cyanosis (late)
 - Fatigue
- Differential Diagnosis:
 - Infection
 - Allergies
 - Cardiac causes (pericarditis)
- Late diagnosis may lead to chronic, irreversible lung disease²

Pneumonitis

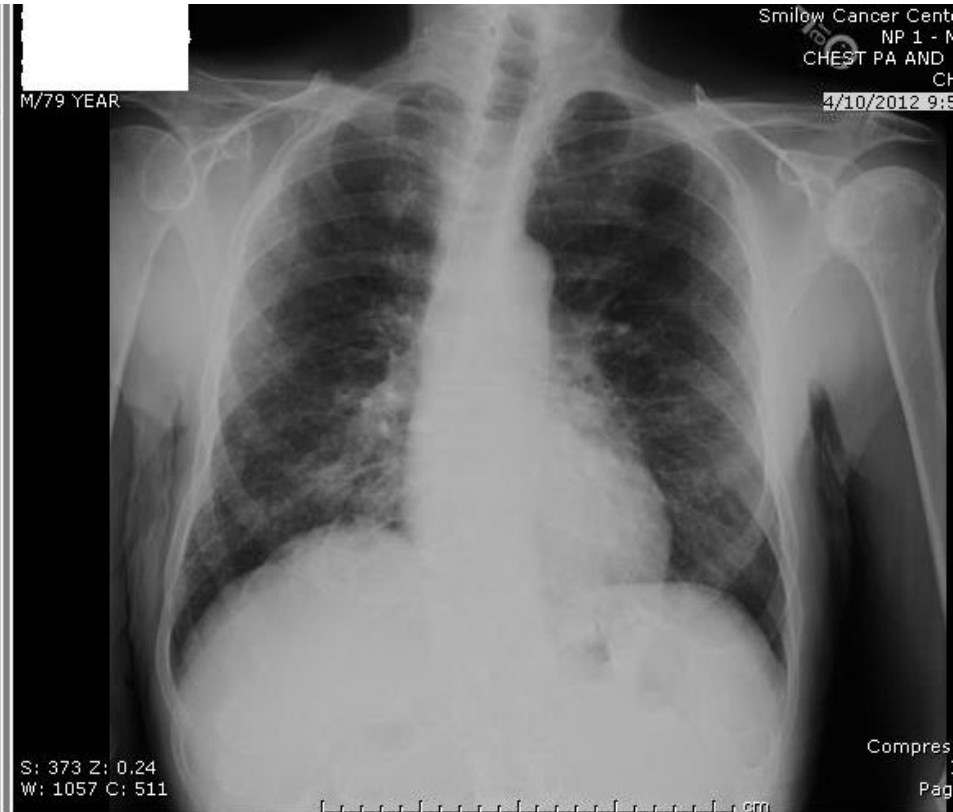- Work-Up:
 - CXR and/or CT scan
 - Radiographic findings of ground-glass lesions and/or disseminated nodular infiltrates
 - Bronchoscopy
 - Pulmonary Function Testing (PFT)
 - Blood Gas
- Treatment:
 - Steroid therapy (guided by radiographic/symptomatic response)
 - Prophylactic antibiotic/antifungal therapy during high dose steroid
 - Mycophenolate mofetil, cyclophosphamide or infliximab in severe cases^{1,2}

Pneumonitis

CXR showing increased interstitial markings compared to baseline



Baseline



After 2 doses PD1/CTLA4

Hepatitis

•Incidence

- Less common than colitis, seen in 2 to 9% of patients and at least 1 death has been reported on anti-CLTA-4 therapy alone¹
- Incidence with anti-PD-1 closer to 0.5%²
- Hepatotoxicity appears worse when ipilimumab combined other drugs including dacarbazine³ and vemurafenib⁴,
- Combination therapy 15-18% overall and 6-8% grade 3-4⁵

•Time to onset 8-12 weeks in single agent, sooner in combination⁶

•Symptoms

- Abdominal bloating or pain, dyspepsia, jaundice and nausea
- Usually asymptomatic and diagnosed based on elevated LFT⁶

Hepatitis

- Work Up
 - Hepatitis panel to evaluate for infectious cause
 - CT and/or ultrasound to evaluate for liver metastases or cholelithiasis
 - Patients with hepatitis may have mild hepatomegaly on imaging¹
 - Biopsy (if needed)
 - Diffuse T-cell infiltrate seen on pathology with diagnosis of hepatitis¹
- Treatment
 - High dose steroid (prednisone 1-2mg/kg)
 - Mycophenolate mofetil with steroid for severe cases
 - Infliximab is contraindicated due to hepatotoxic effects²

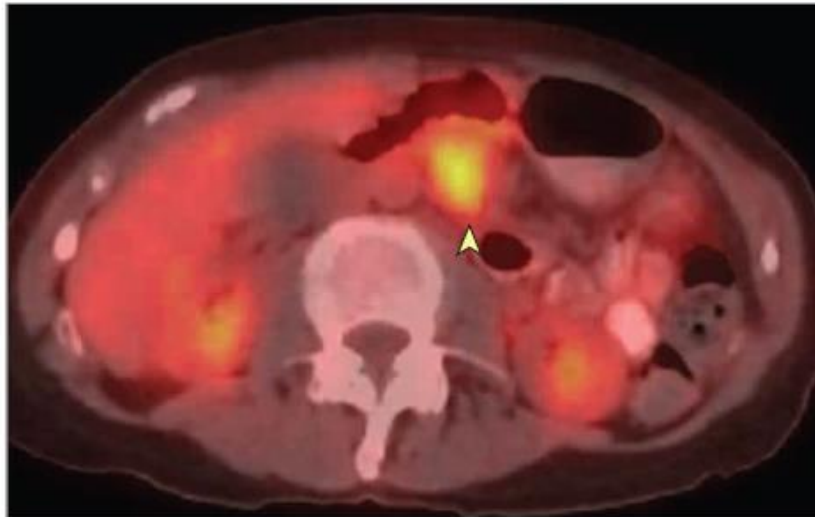
Nephritis

- Seen in approximately 1% of patients on checkpoint inhibitor therapy¹
- Includes:
 - Interstitial nephritis with inflammatory cortical renal enlargement
 - Granulomatous nephritis
 - Glomerular lupus-like nephropathy
- Median time to onset variable (6-30 weeks)²
- Diagnosis to include CMP, urine studies, renal biopsy if needed
- Treatment with steroid

Other irAE

- Pancreatic
 - Asymptomatic elevation in amylase/lipase
 - Pancreatitis
 - Radiographic findings of an inflamed pancreas, elevated amylase/lipase, clinical symptoms
- Clinical relevance of asymptomatic elevations remains unclear¹

B Fluorodeoxyglucose avidity of the pancreas



1. Friedman et al, JAMA Oncology Review, 2016
acc-cancer.org

Other irAE

- Neurologic¹
 - Less than 5% of patients receiving checkpoint inhibitors
 - Includes:
 - Neuropathies
 - Aseptic meningitis
 - Temporal arteritis
 - Myasthenia gravis
 - Guillain-Barre syndrome
- Treatment with steroid not universally effective
 - May need IVIG

Other irAE

- Polyarthrititis/Arthralgia¹
 - Seen in approximately 5% of patients
 - Reported cases erythematous lupus or polymyalgia rheumatic
 - ANA and anti-cyclic citrullinated peptide to detect auto-immune condition
 - Low dose oral steroid to control joint manifestations
- Hematologic toxicity
 - Anemia described in <5% CTLA4 and <10% PD1²
 - Red cell aplasia, autoimmune neutropenia, pancytopenia, acquired hemophilia A also reported¹
 - Work up to include peripheral smear, reticulocyte count, Coomb's test, hemolysis assays and bone marrow biopsy¹

Other irAE

The NEW ENGLAND JOURNAL of MEDICINE

BRIEF REPORT

Fulminant Myocarditis with Combination Immune Checkpoint Blockade

- 2 patients with melanoma who developed fatal myocarditis after treatment with ipilimumab and nivolumab
 - Myositis with rhabdomyolysis
 - Early progressive and refractory cardiac electrical instability
- Myocarditis with robust presence of T-cell and macrophage infiltrates
- Pharmacovigilance studies showing that myocarditis occurred in 0.27% of patients treated with a combination of ipilimumab and nivolumab

Other irAE

Läubli et al. *Journal for ImmunoTherapy of Cancer* (2017) 5:46
DOI 10.1186/s40425-017-0249-y

Journal for ImmunoTherapy
of Cancer

CASE REPORT

Open Access

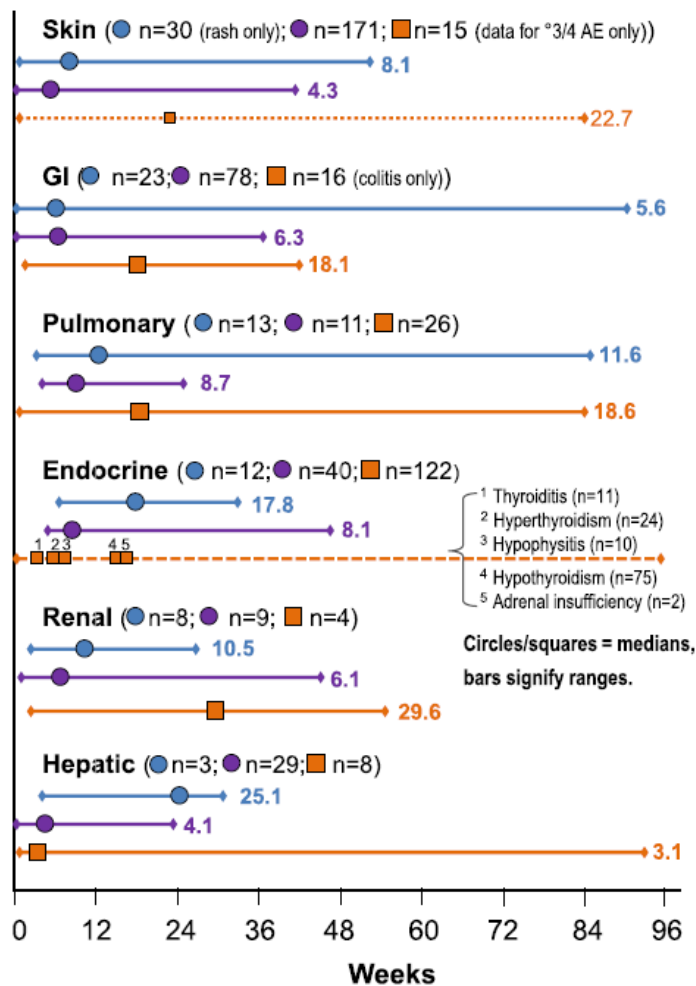


Cerebral vasculitis mimicking intracranial metastatic progression of lung cancer during PD-1 blockade

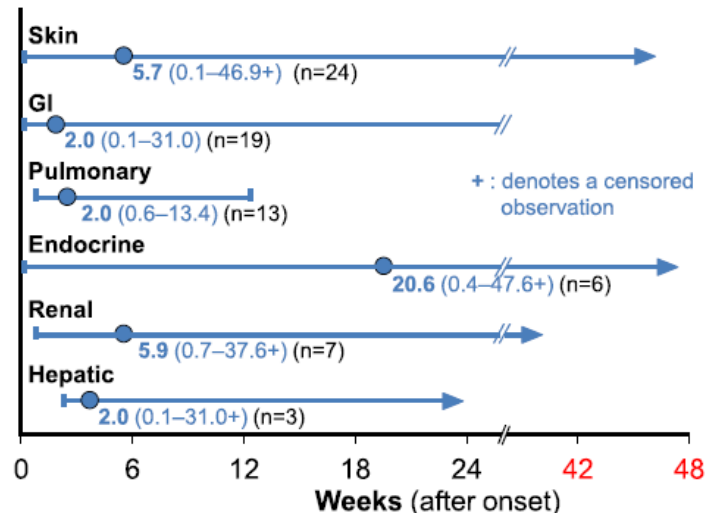
- Metastatic adenocarcinoma patient treated with PD-1
- Developed cerebral lesions while having disease stabilization of extracranial metastases
- Lesion progressed despite stereotactic irradiation
- Resected specimen showed cerebral vasculitis, no cancer
- +ANA and anti-vascular endothelial antibodies in serum

Onset and Resolution

A. Time to onset (median, range)



B. Time to resolution (median, range)



C. Patterns of resolution (percent)

	CA209017/-063 sq NSCLC 3 mg/kg q2w	CA209037/-066 Melanoma 3 mg/kg q2w	P001/-002 Melanoma all regimen
Skin	83%	46%	73%
GI	83%	91%	94%
Pulmonary	100%	50%	65%
Endocrine	50%	44%	12-79% *
Renal	71%	61%	100%
Hepatic	67%	46%	75%

* Range: from 12 % (Hypothyroidism) until 79% (Hyperthyroidism)

Serum Auto-Antibodies

Serum auto-antibody assays with potential value for identifying IRAEs.

Immune-related organ involved	Antibodies
Gastro-intestinal	None
Liver	Antinuclear antibodies (ANAs) Anti-smooth muscle, anti-liver kidney microsomal antibody type 1, anti-liver cytosol type 1
Lung	Antinuclear antibodies (ANAs) Rheumatoid factor Anti-centromere Extractable nuclear antigens (ENA): anti-Sm, anti-RNP; anti-Ro (SSA), anti-La (SSB); anti-Scl70, anti-Jo
Endocrine	Thyroid Diabetes mellitus Addison's disease Hypophysitis
Skin	None
Polyarthritis	Antinuclear antibodies (ANAs) Anti-ENA: Anti-SSA, SSB, Sm Anti-CCP, complement fractions C3 C4 CH50
Renal	Antinuclear antibodies (ANAs) Complement fractions C3 C4 CH50 Anti-neutrophil cytoplasmic (ANCA)
Haematologic syndromes	Antinuclear antibodies (ANAs) Coombs' erythrocyte test

IRAEs = immune-related adverse events; CCP = cyclic citrullinated peptide; GAD = Glutamate decarboxylase; RNP = ribonucleoprotein; Sm = Small nuclear ribonucleoprotein; SSA = Sjogren's syndrome-related antigen A; Scl = Sclerosis systemic; SSB = Sjogren's syndrome-related antigen B; TPO = Thyroid peroxidase.

irAE and Overall Survival

- Cutaneous irAE associated with improved outcomes in melanoma
 - Moffitt Cancer Center study of 148 patients treated with nivolumab plus peptide vaccine or nivolumab alone
 - Statistically significant OS benefit with rash (P=0.0001; HR 0.423)
 - Statistically significant OS benefit with vitiligo (P=0.012; HR 0.184)
 - Rash and vitiligo correlated with OS differences in metastatic disease (P=0.0004 and P=0.028, respectively)
 - No significant survival differences seen with endocrinopathies, colitis or pneumonitis in this study

Table 3. Effect of irAE development on survival, using time-dependent Cox regression analyses

	Univariate				Multivariate			
	HR	LB	UB	P	HR	LB	UB	P
Diarrhea/colitis	0.616	0.343	1.108	0.106	0.632	0.348	1.149	0.132
Hyperthyroidism	2.439	0.682	8.729	0.17	1.604	0.42	6.118	0.489
Hypothyroidism	0.37	0.104	1.325	0.127	0.36	0.1	1.291	0.117
Mucositis	0.09	0.005	1.49	0.093	0.087	0.005	1.448	0.089
Myalgias	0.313	0.019	5.192	0.418	0.377	0.022	6.477	0.502
Pneumonitis	0.346	0.021	5.729	0.459	0.371	0.022	6.313	0.493
Rash	0.427	0.246	0.74	0.002	0.423	0.243	0.735	0.002
Vitiligo	0.178	0.035	0.912	0.038	0.184	0.036	0.94	0.042

irAE and Overall Survival

- Hypophysitis may be associated with improved outcomes
 - Massachusetts General Hospital study of 154 patients treated with Ipilimumab
 - Median survival in patients with ipi-induced hypophysitis was 19.4 vs 8.8 months (P=0.05)

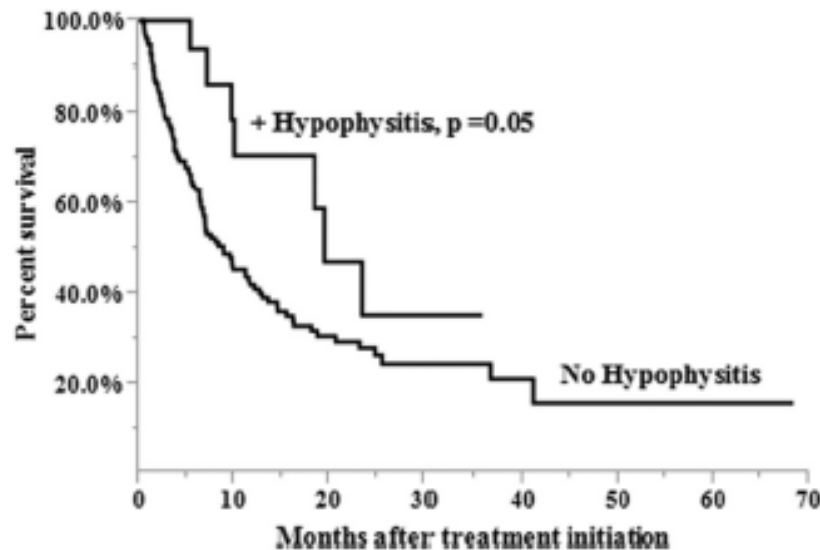


Figure 3. Kaplan-Meier plots for survival in metastatic melanoma patients, with and without hypophysitis, after the initiation of Ipi.

Do Steroids Decrease Effectiveness? Probably Not

- Retrospective study of patients with melanoma treated with ipilimumab
- N = 298
- irAE, any grade: 254 (85%)
- Steroid therapy required: 103 (35%)
- Time to Treatment Failure, Overall Survival: the same in both groups

Case Study #1

Patient DC

65 y/o female with Stage IVa (T2N2bM0) squamous cell carcinoma of the right tonsil

Oncologic history:

10/20/2013: R-sided tonsillectomy w/ pathology revealing poorly differentiated SCCa, HPV/P16+

11/1/2013: PET/CT FDG uptake in right tonsillar pillar (SUV 5.4), no cervical lymphadenopathy noted

11/2013: Right pharyngectomy and right lymph node dissection

Post-op tx w/ XRT and weekly cisplatin, developed tinnitus and then on week 3 switched to carboplatin; tinnitus ultimately resolved

3/11/2016: CT chest revealing 2 separate round nodules; 1 in right lower lobe (1.8x1.5cm) and another in left upper lobe (1.3x1.1cm)

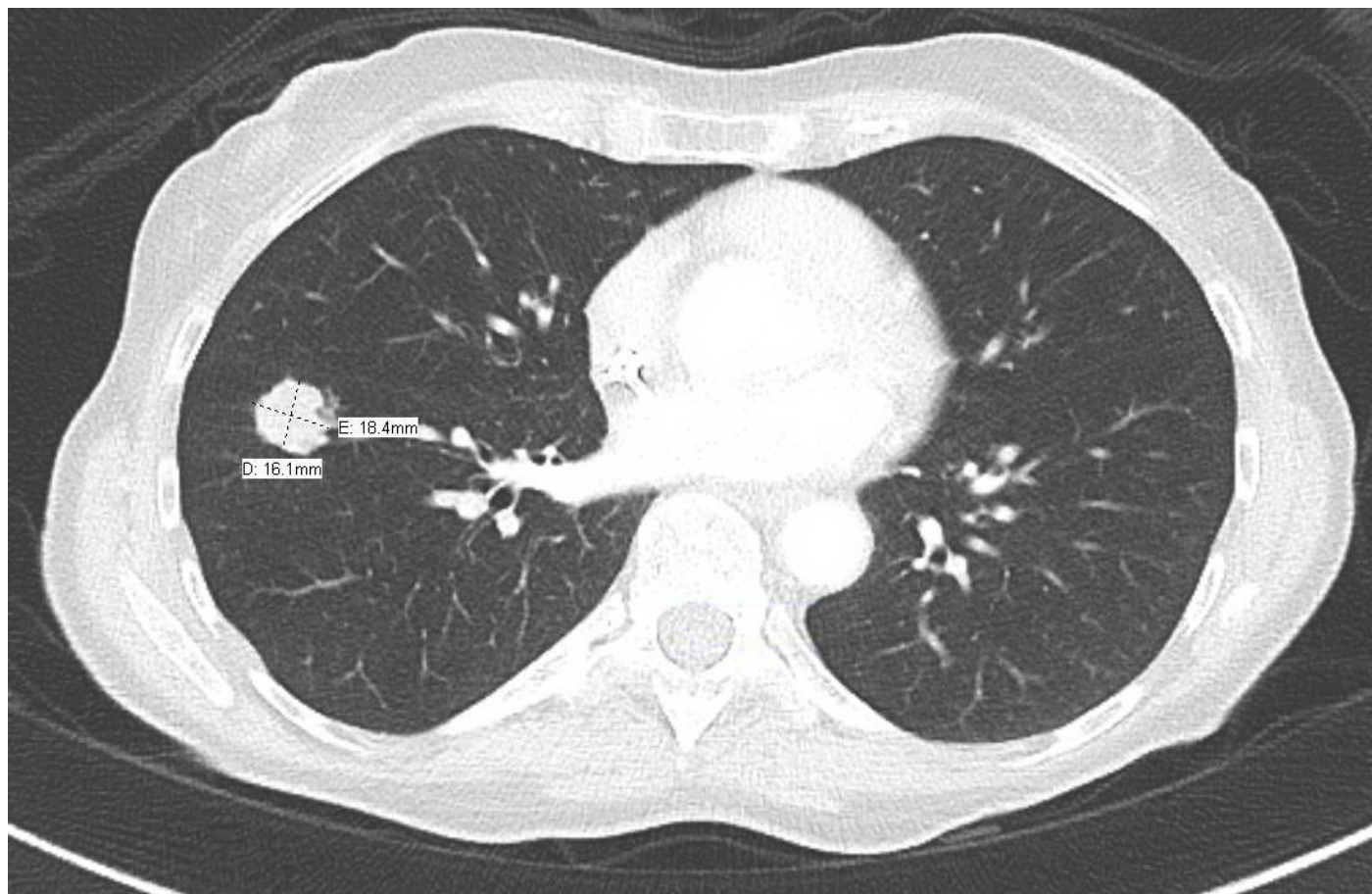
3/14/2016: PET/CT revealing left upper lobe and right lower lobe pulmonary nodules with intense associated increased uptake consistent with pulmonary metastatic disease, new since prior PET/CT; no evidence of local recurrence in pharyngeal soft tissues

3/17/2016: CT-guided biopsy of new PET positive lung nodules -> path: SCCa

4/29/16-10/4/16: Started EXTREME with 5FU, Carbo and Cetuximab, 5FU stopped at cycle 2, Carbo stopped at cycle 7

11/14/16: Started on Pembrolizumab

Patient DC



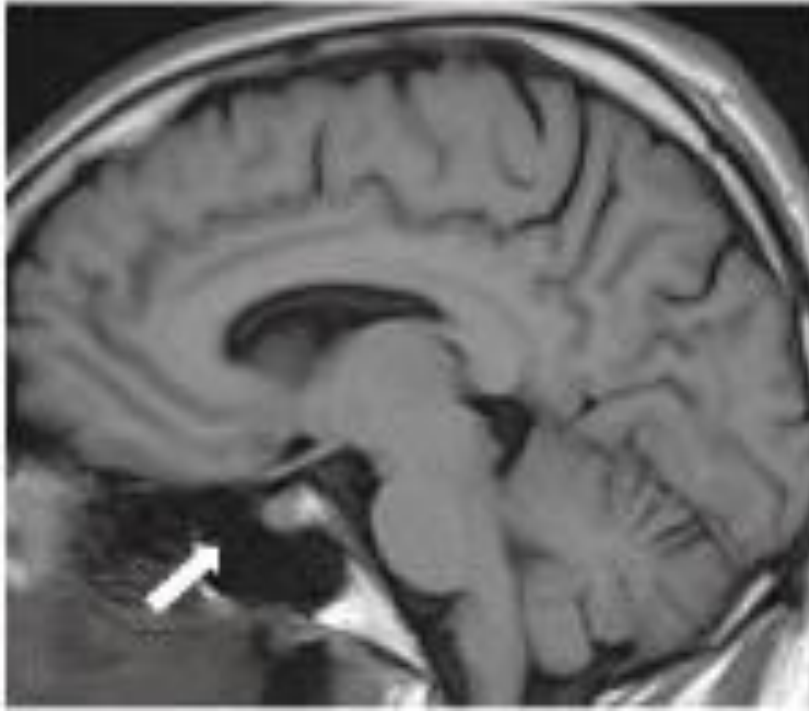
Right lung nodule prior to initiation of pembrolizumb (10/13/16)

Patient DC

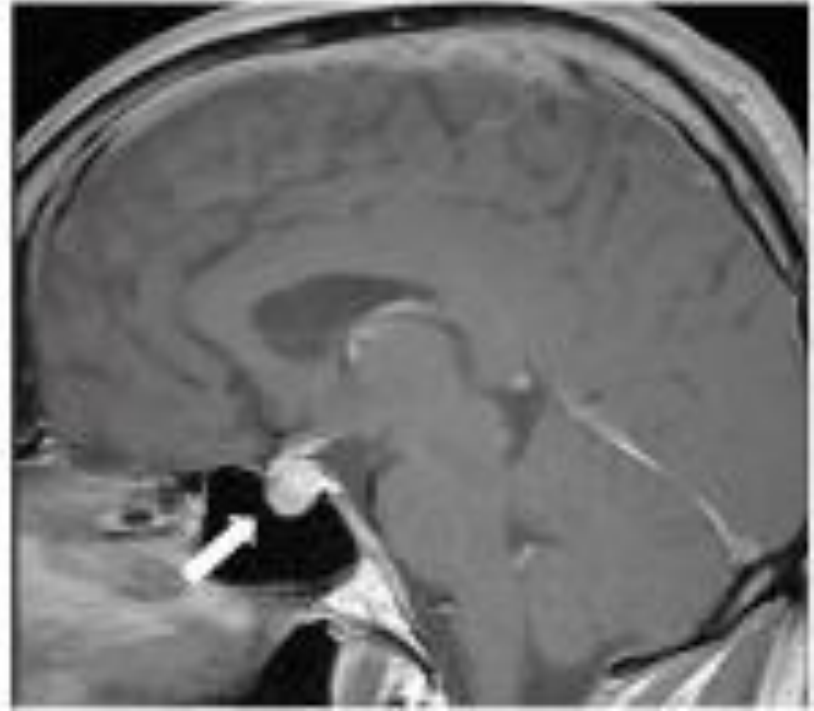
- Tolerating therapy well through the first three cycles
 - Mild joint pains controlled with 10mg prednisone
- 1/20/17 presents for C4D1 pembrolizumab
 - Complains of headaches, dizziness, fatigue
 - Looks unwell
 - Obtain MRI brain with pituitary cuts
 - Check thyroid function

	ACTH (pg/ml)	TSH (ml/UL)	T4 (ng/dL)
Pre	30	1.3	1.1
Post	4	0.39	0.3
Reference	10-50	0.5-5.5	0.89-1.76

Patient DC



Pre-treatment



Prior to cycle 4

Patient DC

- Grade 2 adrenal insufficiency due to hypophysitis
 - Initiated on hydrocortisone 20mg QAM, 10mg QPM
- Grade 2 hypothyroidism due to hypophysitis
 - Initiated on levothyroxine 100mcg PO daily
- OK to continue pembrolizumab

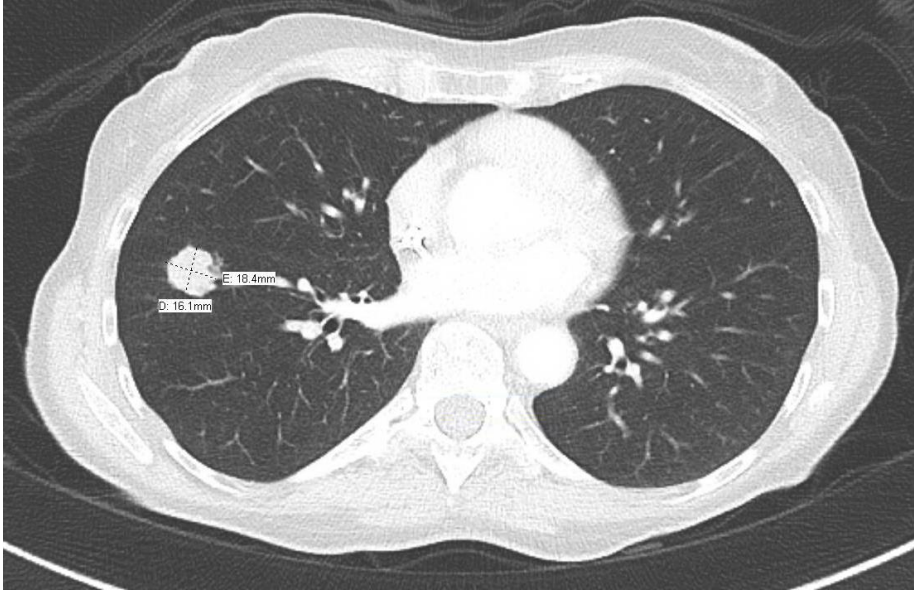
Patient DC

- Presents 4/14/17 for C8 Pembrolizumab
 - Lethargic, tachycardic
 - Complains of severe thirst and frequent urination
 - Random glucose 524
 - Admit for emergent management and work-up

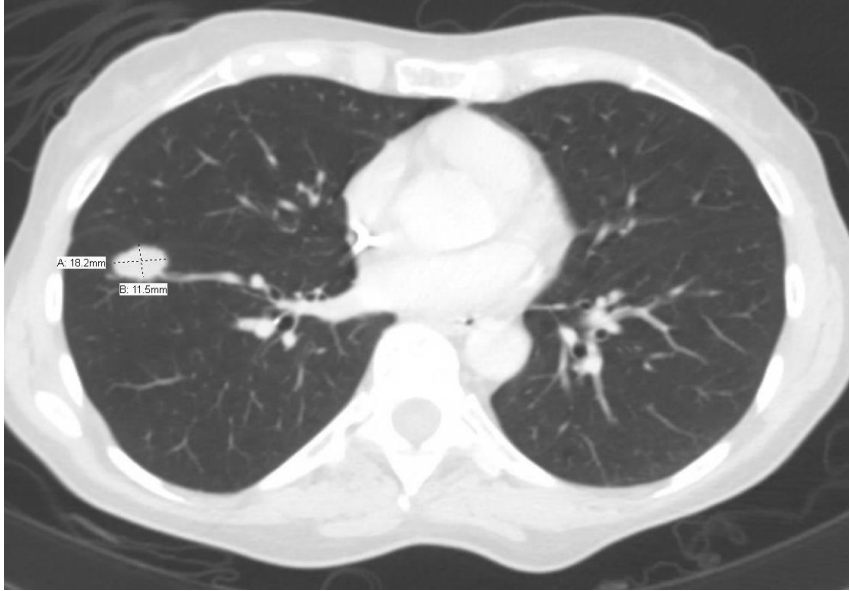
Patient DC

- Glutamic acid decarboxylase 65 (GAD65) antibodies positive
- Diagnosed with new onset DM1 secondary to pembrolizumab
- Pembrolizumab discontinued
- Patient initiated on life-long insulin therapy

Patient DC



Baseline



After 7 Cycles of Pembrolizumab

Case Study #2

Patient MM

- 78 year old male with IV melanoma with widely metastatic melanoma diagnosed 6/2016
- PMH: Hypertension, Hypercholesterolemia, Asthma, Vitiligo
- PSH: Hernia repair, back surgery
- Medications: lisinopril, lorazepam, simvastatin, oxycodone

Patient MM

- Baseline PET scan showing widely metabolic disease

3D Volume 2
Ex: 3987
Se: 3
HD MIP No cut

DFDV 100.1 cm
300/21

MidState

M 79
DoB:
Ex: Dec 28 2011

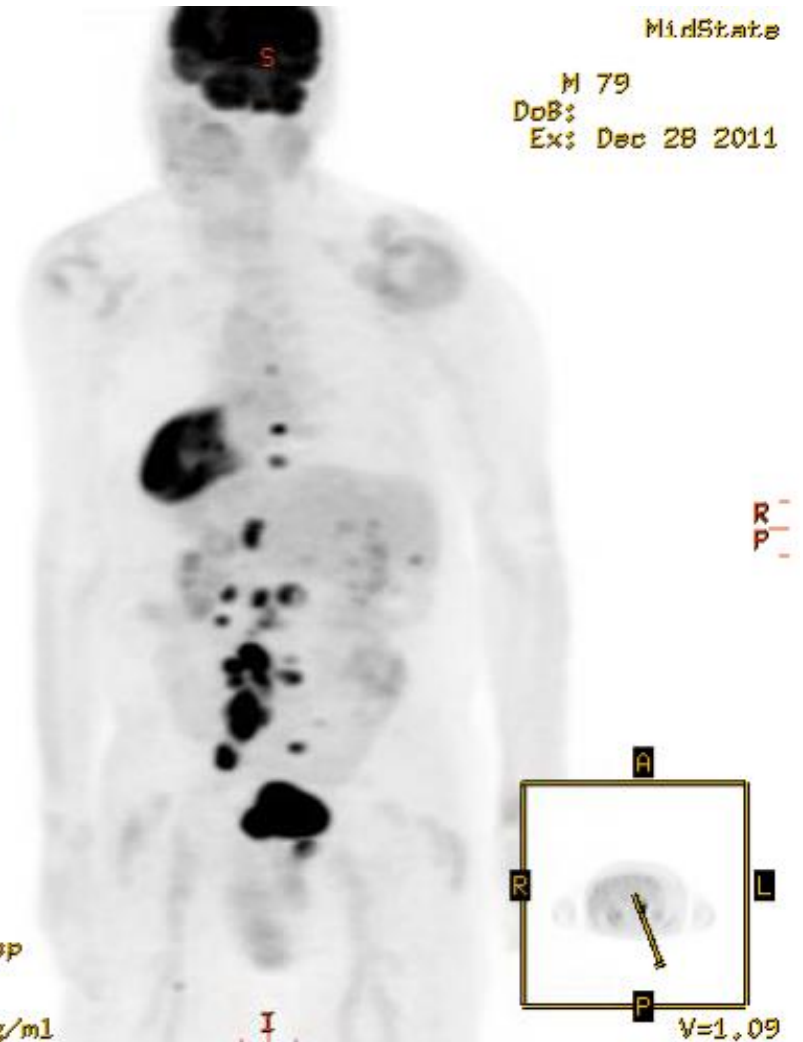
L
A

R
P

No VOI

3.3mm /3.3var.sp

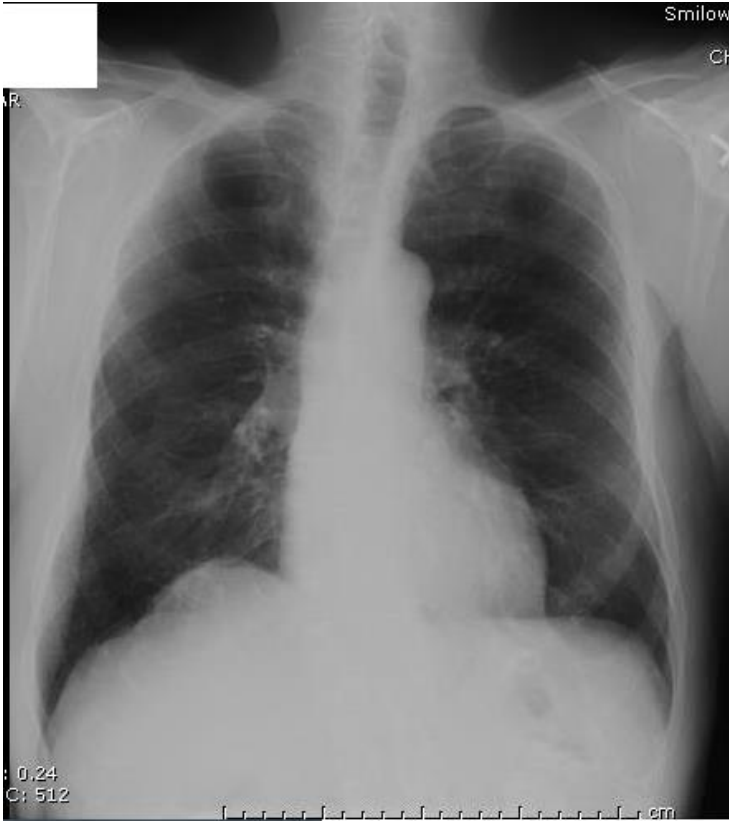09:06:48 AM
m=0.00 M=5.00 g/ml



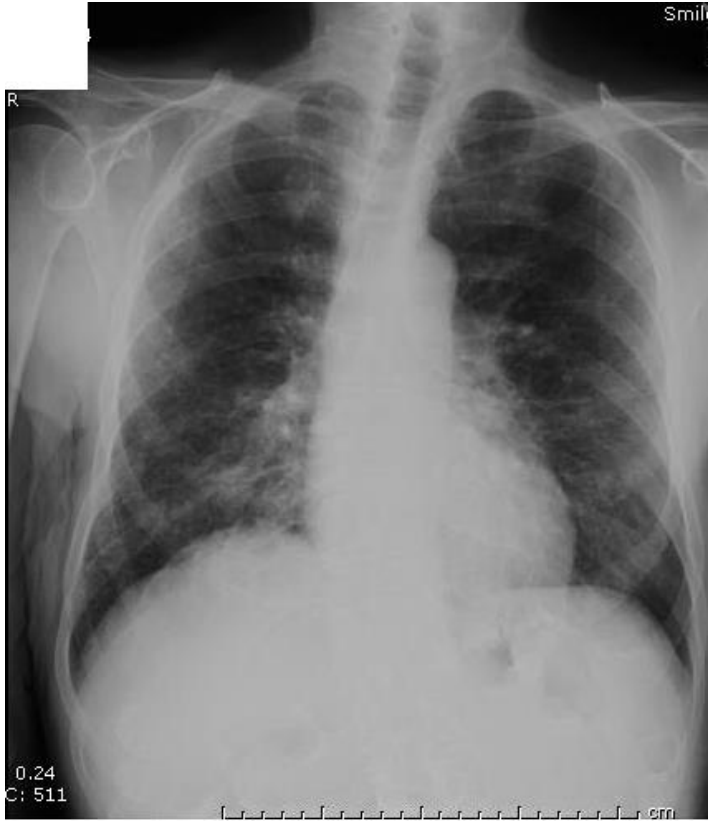Patient MM

- Initiated on Ipilimumab (3mg/kg) + Nivolumab (1mg/kg)
 - C1D1 7/1/16
 - C2D1 7/22/16
 - C3D1 8/19/16
- 8/27/16 patient presents to outside hospital complaining of fever, cough and shortness of breath
 - VS: BP 125/86, HR 90, RR 22, O2 90%, Temp 100.1
 - CXR: Read as RML pneumonia
 - Patient initiated on Augmentin 875mg/125mg Q12

Patient MM



Baseline



8/27/16

Patient MM

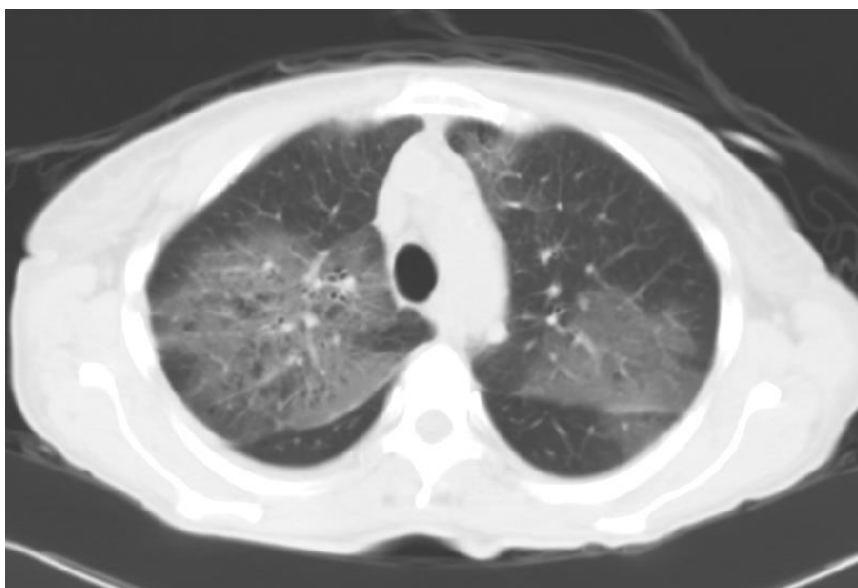
- 8/30/16 patient presents to clinic with continued low grade fever, cough and diarrhea since 8/29/16
- Denies sick contacts, dietary changes
- Approximately 8 loose bowel movements per day (baseline 1 BM daily)
- No relief with imodium
- Cough making it difficult to sleep at night

Patient MM: Differential Diagnoses

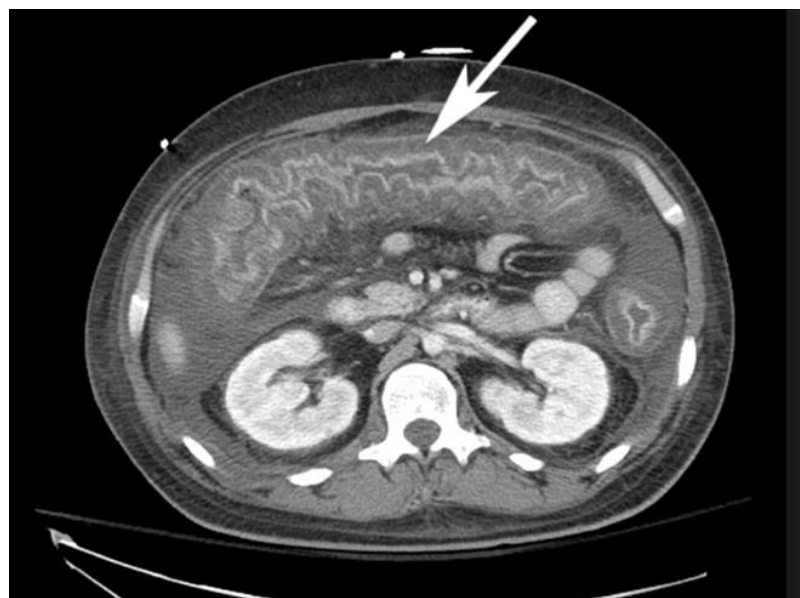
- Grade 3 Diarrhea Differential Diagnoses:
 - Infectious diarrhea (including c-diff)
 - Antibiotic associated diarrhea
 - Colitis secondary to immunotherapy
- Grade 3 Cough v Pneumonitis Differential Diagnoses:
 - Infectious
 - Inflammatory
 - Irritation

Patient MM: Imaging

Chest CT scan:



Abdominal CT scan:



Patient MM: irAE Diagnoses

- Grade 3 Colitis and Grade 3 Pneumonitis
 - Initiate steroid at 1mg/kg of solumedrol or equivalent
 - Recommend IV steroid initially with colitis symptoms due to gut absorption issues
 - Taper slowly (one month)
 - Consider antibiotic prophylaxis during high dose steroid
 - Discontinue immunotherapy

Patient MM

3D Volume 2
Ex: 3987
Se: 3
HD MIP No cut

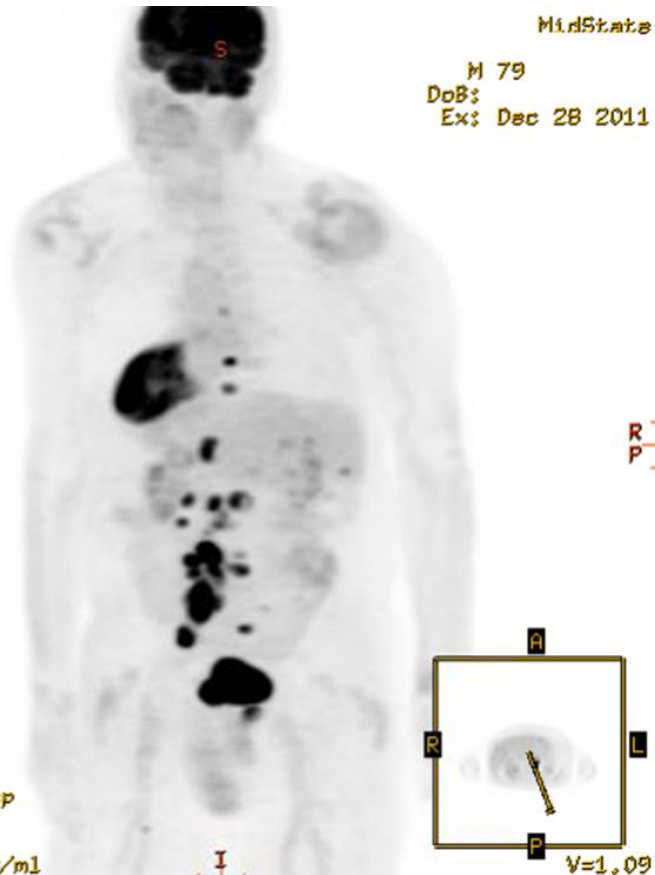DFDV 100.1 cm
300/21

L
A

No VOI

3.3mm /3.3var.sp

09:06:48 AM
m=0.00 M=5.00 g/ml



Baseline

3D Volume 2

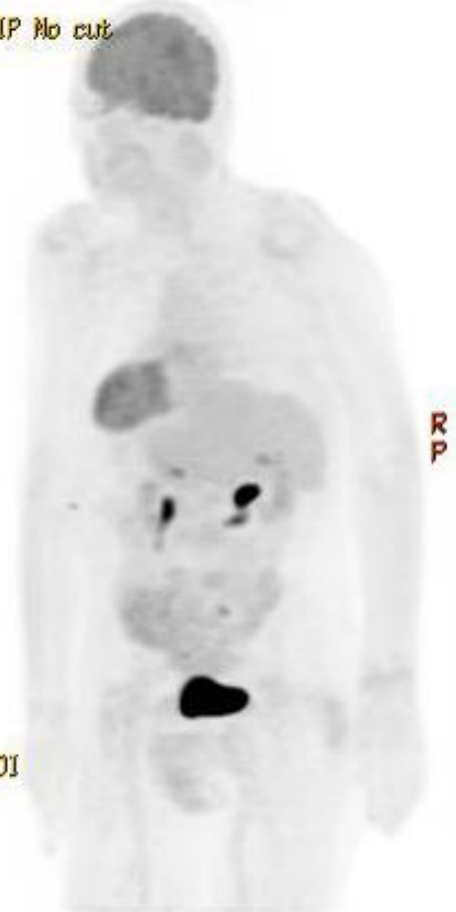
DFDV 65.0 x 130.0 cm ^S Sep 14 2012

HD MIP No cut

L
A

No VOI

m=0.00 M=11.18 g/ml I -999999.000000



After three doses

QUESTIONS

Thank you for participating in the ACCC/OSSN Webinar. Presentation slides and archived recording will be available at acc-cancer.org.



This project is made possible by an educational donation from EMD Serono.

