

Hyperviscosity Related to Waldenström Macroglobulinemia Treated with Plasmapheresis

Austin Cudak DO¹, Stuart Bloom MD², Susan Wheaton MD³, Samith Kochuparambil MD²

1) Abbott Northwestern Department of Internal Medicine, 2) Minnesota Oncology, 3) Hospital Pathology Associates

INTRODUCTION

- Waldenström macroglobulinemia (WM) is a lymphoplasmacytic lymphoma (LPL) with high levels of circulating IgM paraproteins.
- This is a rare disease with 1400 new cases diagnosed in the United States each year¹.
- Intravascular IgM proteins can cause a hyperviscosity syndrome resulting in neurologic symptoms, epistaxis, ophthalmoscopic changes.
- Several molecular mutations are associated with WM including a MYD88 L265P mutation present in >90% of patients¹.

CASE #1

- A 55-year-old man presented with vision changes and had a neurologic workup with negative head MRI/MRA. His symptoms improved overnight after treatment with intravenous fluids and he was discharged.
- Laboratory evaluation later resulted showing significant elevation on his serum protein electrophoresis with a monoclonal gamma globulin of 8.26 g/dL. He was instructed to return to the hospital.
- CT imaging was obtained which showed significant mediastinal and retroperitoneal lymphadenopathy with severe splenomegaly. Given the clinical context, and waxing and waning vision changes, he was emergently started on treatment with plasmapheresis.
- Immunoglobulin laboratory evaluation showed IgM elevated to 10.6 g/dL and remainder of pathologic workup with bone marrow and lymph node biopsy consistent with LPL. The bone marrow sample was notably sent for molecular studies and it was positive for the MYD88 L265P alteration.
- He was then treated with rituximab and bendamustine.

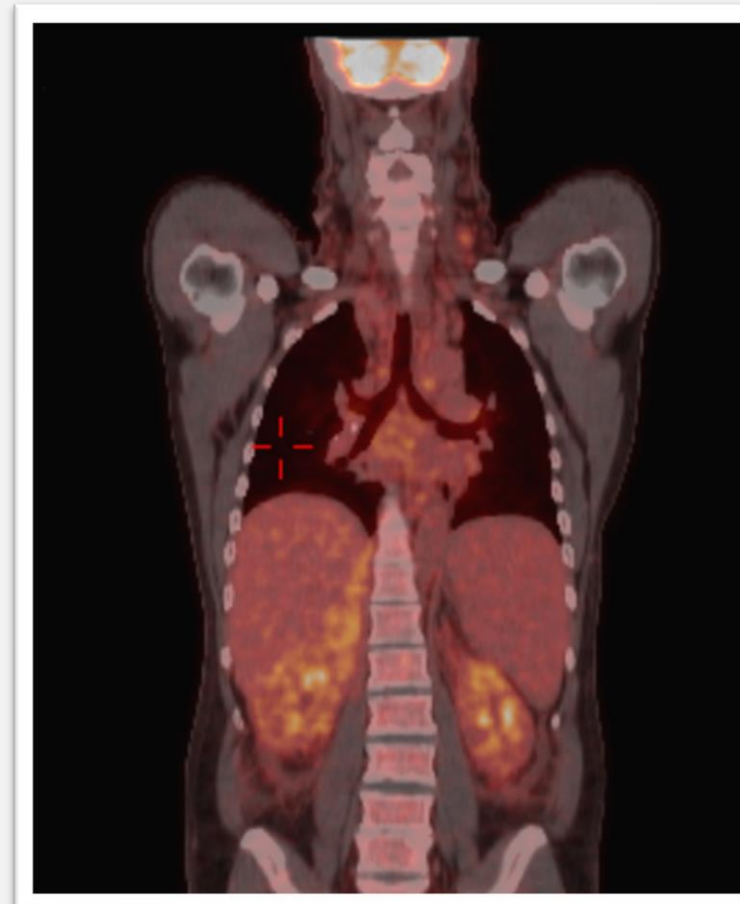

Figure 1. PET CT scan prior to treatment showing Cervical and paratracheal lymph node enlargement.

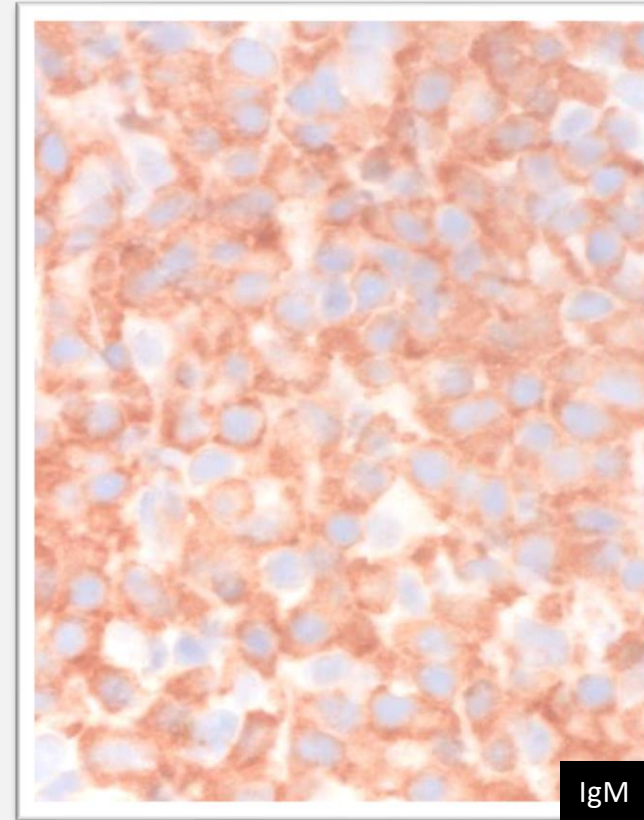


Figure 2. Fine needle biopsy of the left supraclavicular lymph node with IgM staining.

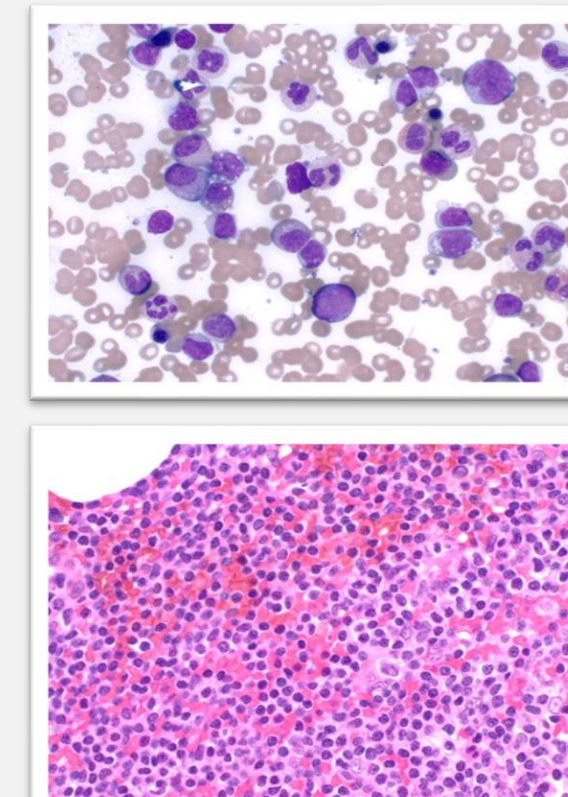


Figure 3 and Figure 4. Bone marrow biopsy showing numerous well-defined interstitial and paratracheal lymphoid aggregates comprised of small mature-appearing lymphocytes with subtle plasmacytoid features.

CASE #2

- A 75-year-old woman with a past medical history of B cell lymphoma several years prior presented with vision changes to an ophthalmologist. However, as this was under evaluation she presented to the ED with acutely worsening dysphagia and difficulty breathing and was subsequently admitted to the ICU.
- CT of the head and neck showed bulky lymphadenopathy (Figure 5) concerning for airway compromise along with a mass in the right orbit. Laboratory evaluation showed serum immunofixation with an IgM of 10.2 g/dL.
- Plasmapheresis was initiated emergently. Given the clinical context she was treated with rituximab, steroids, and bendamustine as well.
- Axillary lymph node biopsy showed cytoplasmic immunoglobulin IgM, consistent with lymphoplasmacytic lymphoma. Peripheral blood showed prominent B cell lymphocytosis (Kappa clonal and negative for CD5, CD10, and CD23). The combination of the clinical findings and lymphocyte morphology/immunophenotype confirmed the diagnosis of lymphoplasmacytoid lymphoma.

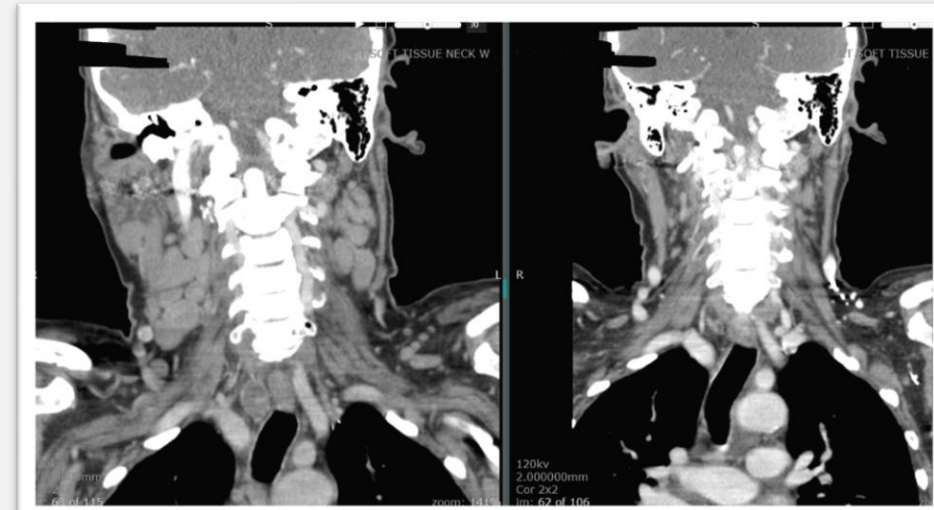

Figure 5. CT soft tissue of the neck with interval improvement in cervical lymphadenopathy after treatment (4mo later). The first CT scan also showed a mass in the right orbit compatible with intraorbital lymphoma and also prominent nasopharyngeal adenoidal tissues compatible with lymphoma.

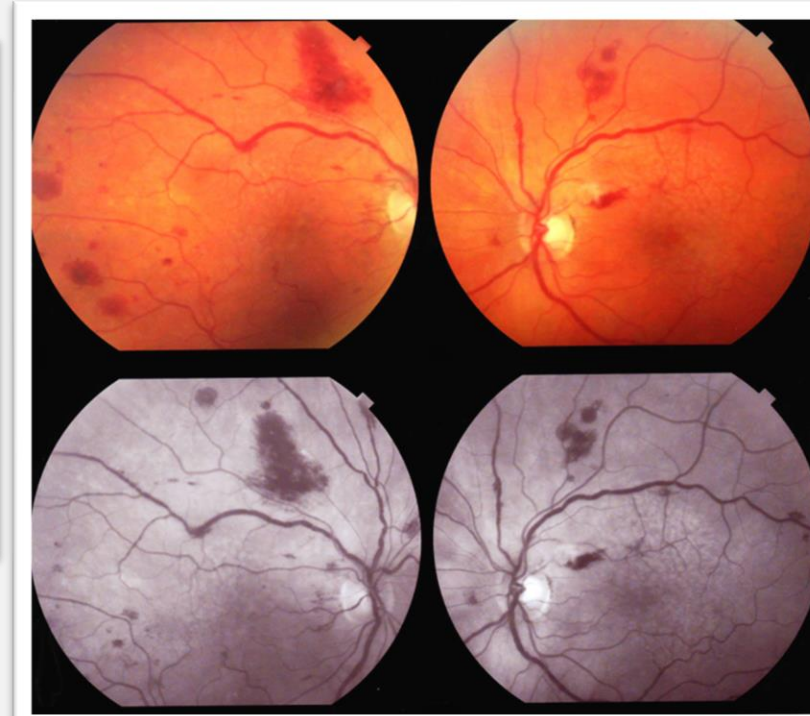


Figure 6. Retinopathy prior to treatment with fundoscopic exam showing multiple hemorrhages and tortuous retinal veins.

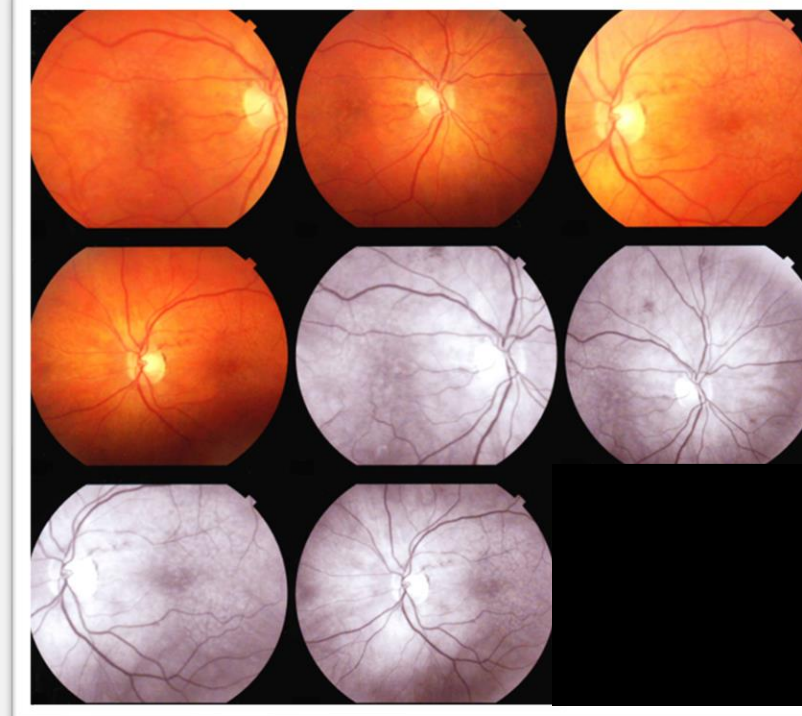


Figure 7. Noted improvement in retinopathy after treatment (these images were obtained about four months after the images in Figure 6).

DISCUSSION

- These cases illustrate the importance of prompt recognition of hyperviscosity syndrome related to Waldenström Macroglobulinemia. The threat of neurologic compromise may require plasma exchange or plasmapheresis prior to the completion of evaluation. Other cases in the literature have also demonstrated life-threatening affects of Waldenström Macroglobulinemia such as retinopathy and renal disease^{2,3}. Lastly, several other cases recognize the severity of neurologic complication of Waldenström Macroglobulinemia^{4,5}.
- Rapid diagnosis is often difficult due to the heterogeneous presentation of the disease⁶.
- The first case additionally shows that the pathologic diagnosis of LPL can be complex and requires special staining as well as specific molecular studies. The second case adds to the already known fundoscopic abnormalities noted with WM that are associated with hyperviscosity further demonstrating the importance of fundoscopic examination⁷.

TAKE HOME POINT

Awareness and prompt recognition of presenting neurologic symptoms in Waldenström Macroglobulinemia allows punctual diagnosis and initiation of time-sensitive treatment.

REFERENCES

1. Harrison's Principles of Internal Medicine, by J. Larry Jameson et al., McGraw-Hill Education, 2018, pp. 777–804.
2. Naoko Kudo, Masakatsu Usui, Yukiharu Nakabo, Ken-ichi Yoshida, Kenji Miki, Takashi Osafune, Keisuke Nishimura, Shinsaku Imashuku, "Waldenström's Macroglobulinemia: A Report of Two Cases, One with Severe Retinopathy and One with Renal Failure", *Case Reports in Hematology*, vol. 2017, Article ID 3732902, 6 pages, 2017. <https://doi.org/10.1155/2017/3732902>
3. Marcel N. Menke, Gilbert T. Feke, J. Wallace McMeel, Steven P. Treon; Effect of Plasmapheresis on Hyperviscosity-Related Retinopathy and Retinal Hemodynamics in Patients with Waldenström's Macroglobulinemia. *Invest. Ophthalmol. Vis. Sci.* 2008;49(3):1157-1160. doi: <https://doi.org/10.1167/iov.07-1254>.
4. Ananth Arjunan, Hema Rai, "Central Nervous System Involvement by Waldenström Macroglobulinemia: A Case Report of the Bing-Neel Syndrome", *Case Reports in Hematology*, vol. 2019, Article ID 4075960, 3 pages, 2019. <https://doi.org/10.1155/2019/4075960>
5. Costa, Paulo Zoé et al. "Waldenström Macroglobulinemia and Cerebral Venous Thrombosis: From Diagnosis to Complication." *Case reports in medicine* vol. 2019 9581605. 14 Jul. 2019, doi:10.1155/2019/9581605
6. Kolikkat Nejima, Moideen Shamsudeen, Khader Aysha, Mohammed T P, Uvais N A, "Waldenström's Macroglobulinemia: A case report" *Journal of family Medicine and Primary Care*, Volume 9, Issue Number 3, Page 1768-1771.
7. García-Sanz R, Montoto S et al.,; Spanish Group for the Study of Waldenström Macroglobulinaemia and PETHEMA (Programme for the Study and Treatment of Haematological Malignancies). "Waldenström macroglobulinaemia: presenting features and outcome in a series with 217 cases." *Br J Haematol.* 2001 Dec;115(3):575-82. doi: 10.1046/j.1365-2141.2001.03144.x. PMID: 11736938.